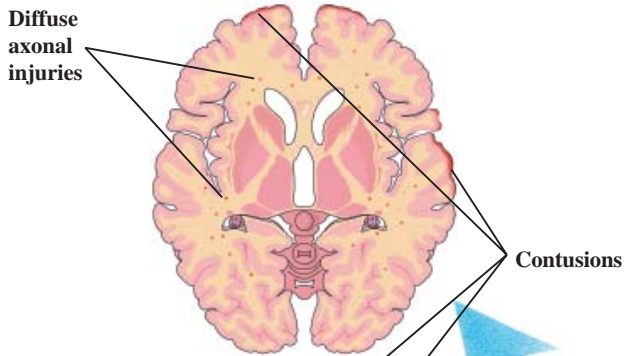
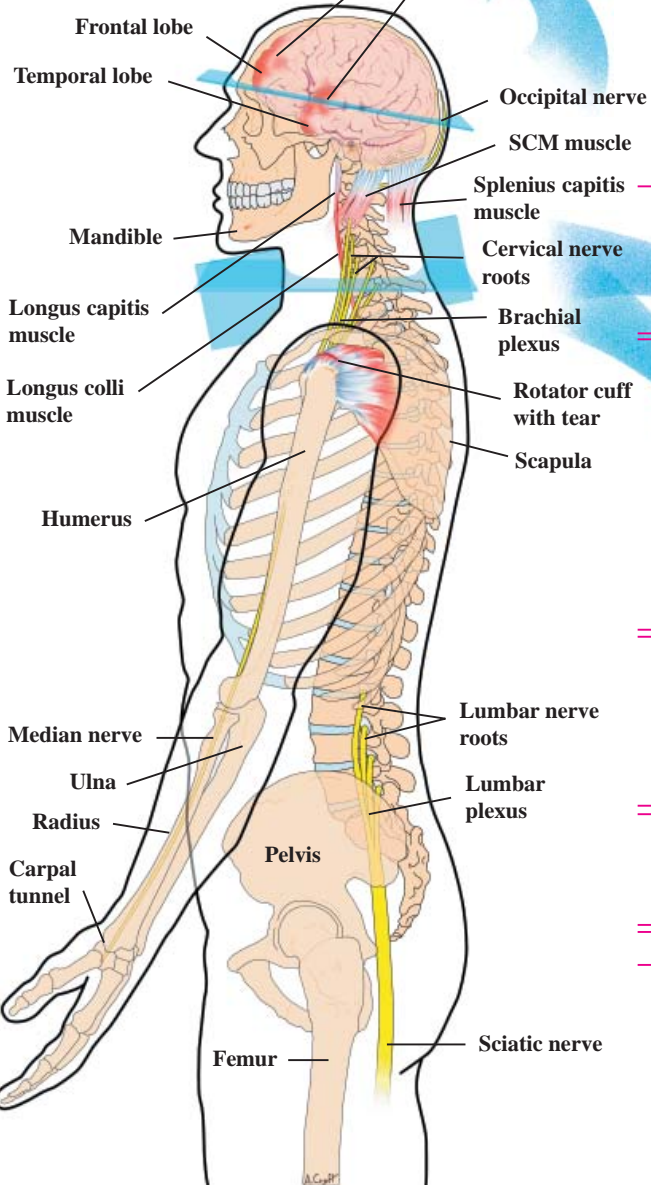
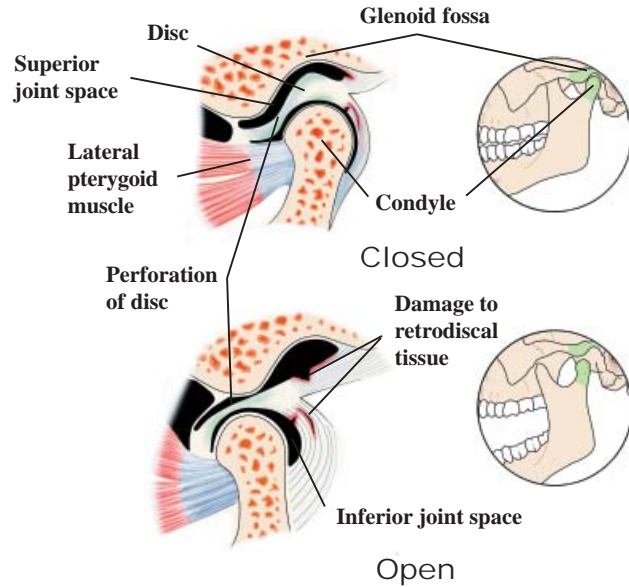


Anatomy of Whiplash Injuries

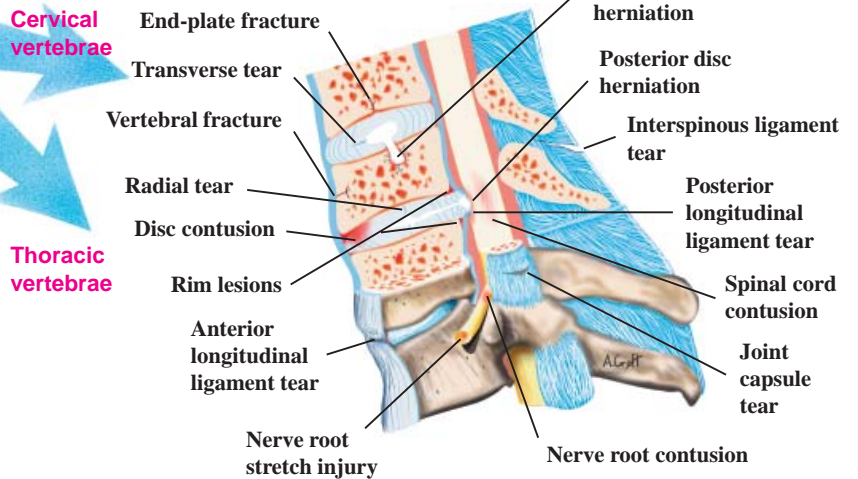
Brain injuries



Temporomandibular joints



Spinal injuries



Cervical vertebrae

Thoracic vertebrae

Lumbar vertebrae

Sacrum

Coccyx

